

Chief Complaint

64 year old male presents with the chief complaint "I want to fix my smile"

Past Medical History

- Basal Cell Carcinoma 2016, 2017 - treated with excisional biopsies
- Tonsillectomy
- No medications and no known allergies
- Smokes 1 ppd

Dental History

- Restorative work done in 1980's including upper and lower fixed dental prostheses
- Last outside dental visit 1990's
- Presents to Upenn School of Dental Medicine 2020
- Remaining dentition: #1-7,11,12,14,15, 17,18,21,22,27-32
- #6 impacted
 - Metal mesh placed in defect along with collatape
 - With removal of impacted #6, #11 + 12 fail (fractured)
 - Dehiscence of #10 with gutta-percha exposure
 - Fixed dental prosthesis no longer viable
- Lower left mandibular cyst
 - Removed via excisional biopsy + peripheral osteotomy
 - Biopsy result → Odontogenic keratocyst

Treatment Plan

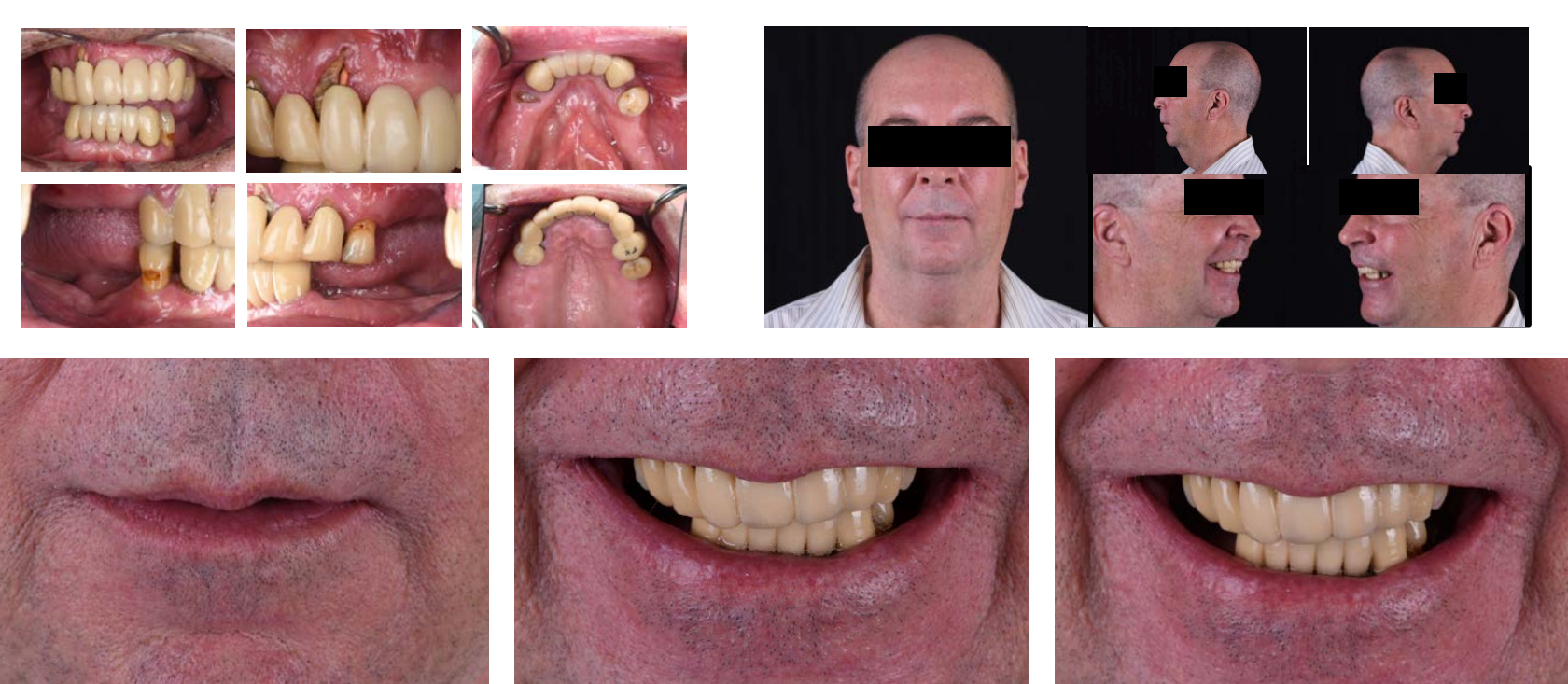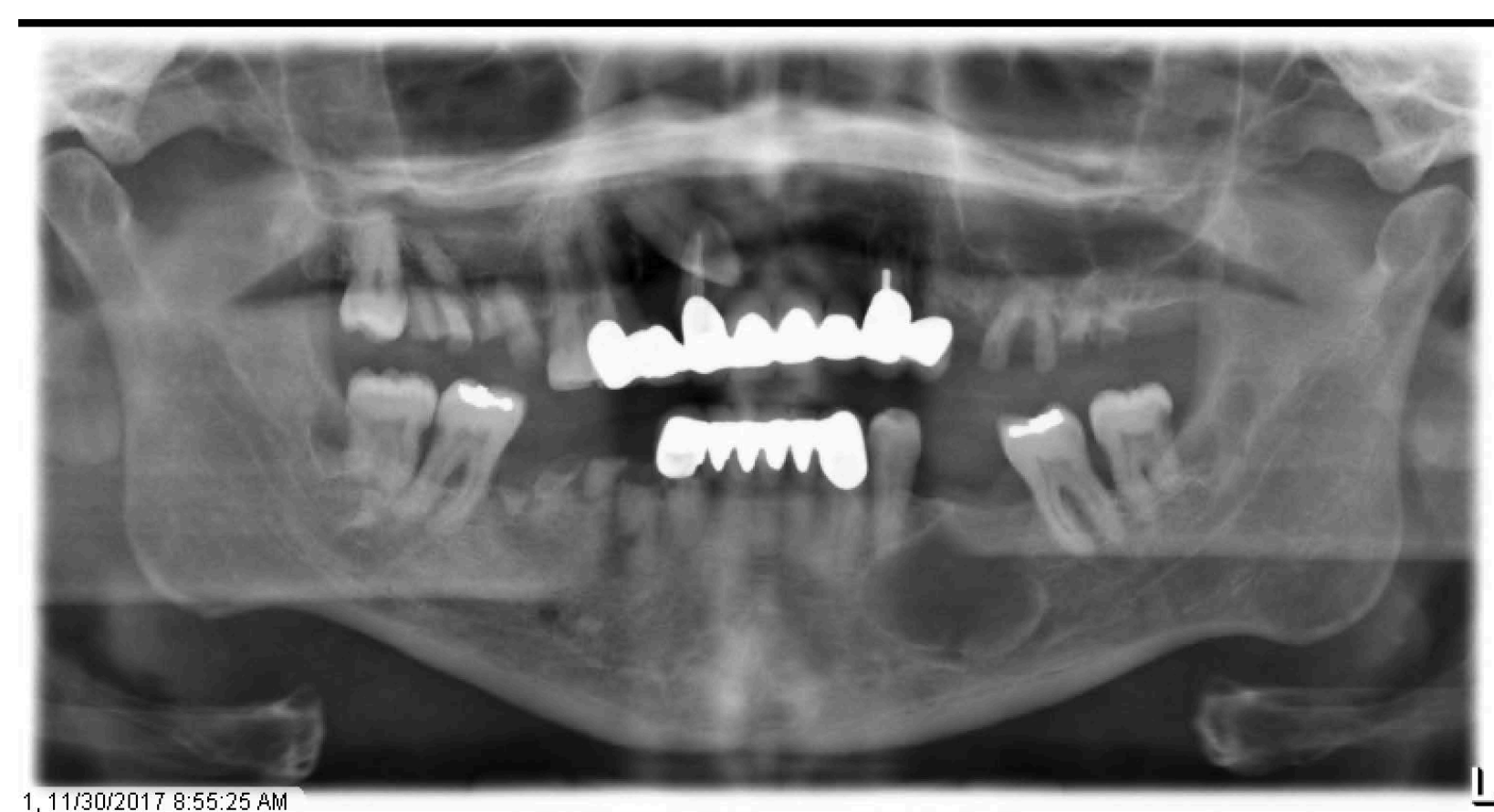Treatment Options

1. Complete maxillary and mandibular dentures
 2. Implant stabilized overdentures
 - Maxillary- 4 implants
 - Mandibular- 2 implants
 3. Implant supported hybrid prostheses
- Patient opted for option #2 for function and financial reasons.

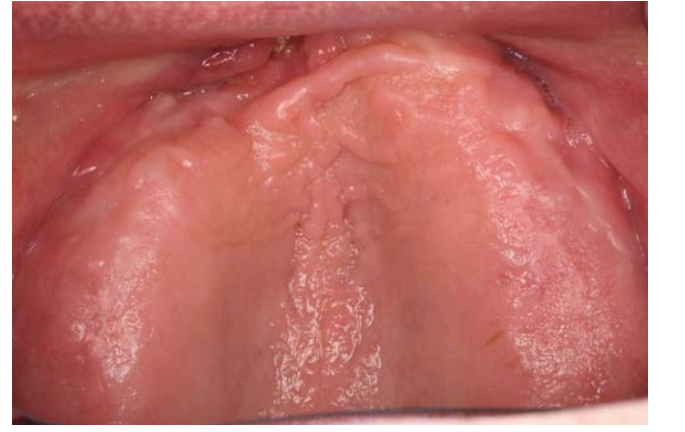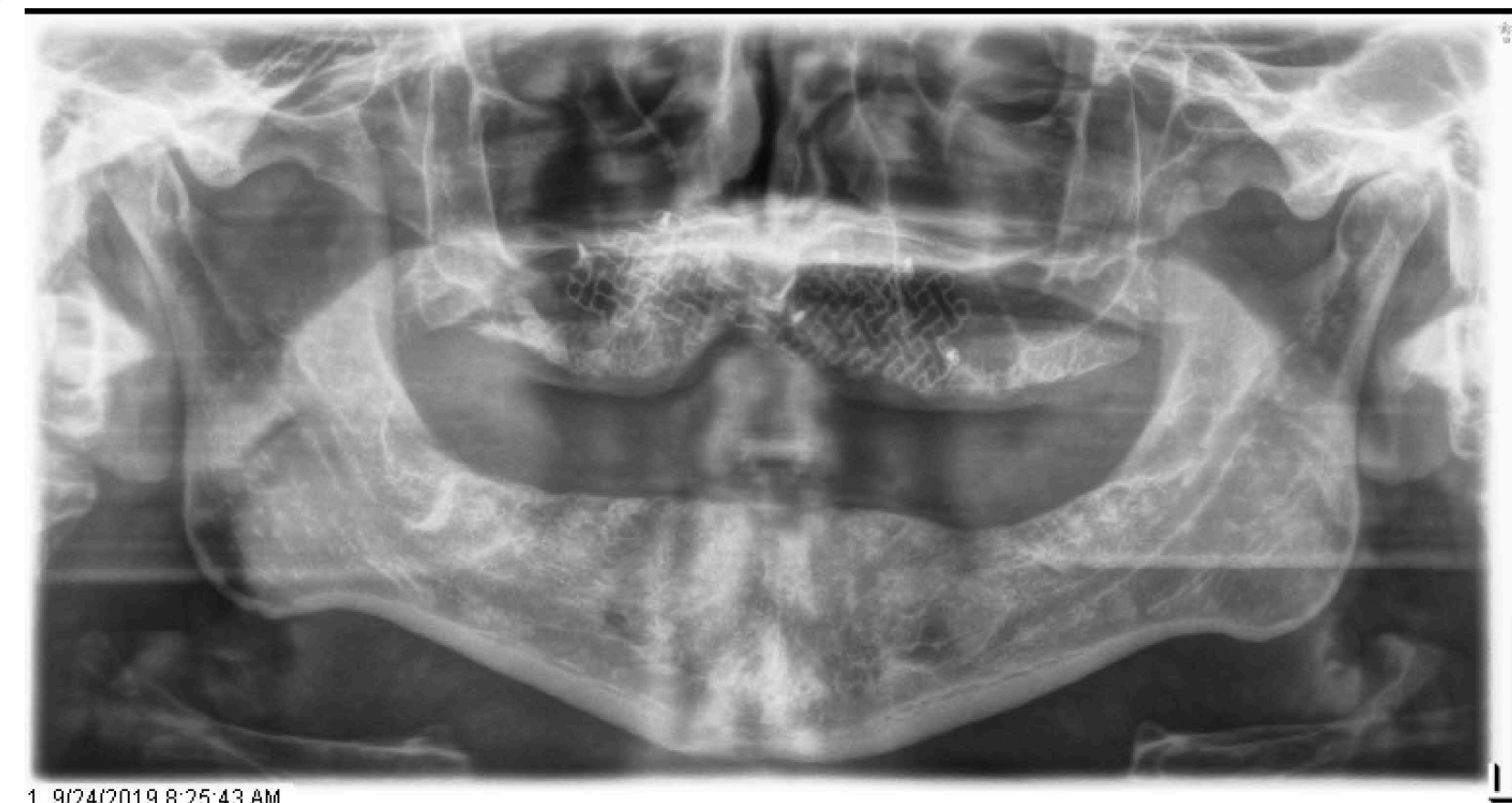Pre-Prosthetic Surgery

- Required for all three treatment options
 - Guided tissue regeneration at sites #4,6,12
 - Bone grafting at sites #4,5,7,12
 - Interim denture failed due to maxillary alveolar defect and lack of retention

Panoramic Radiograph, Intra-oral Images, Facial/Smile Analysis

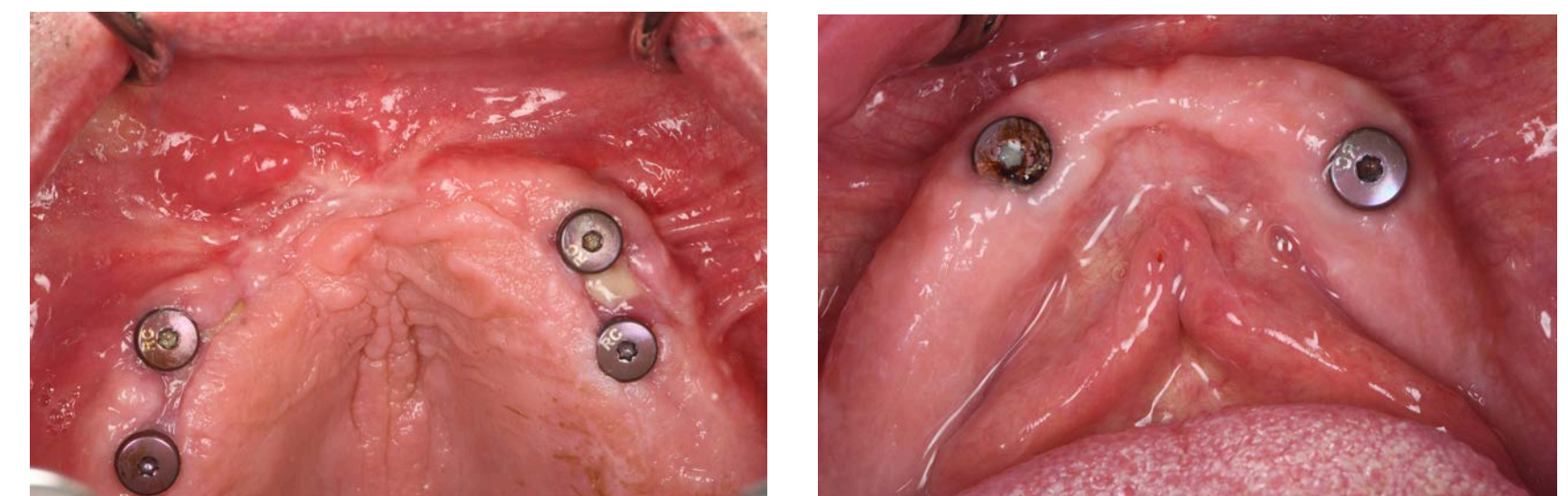
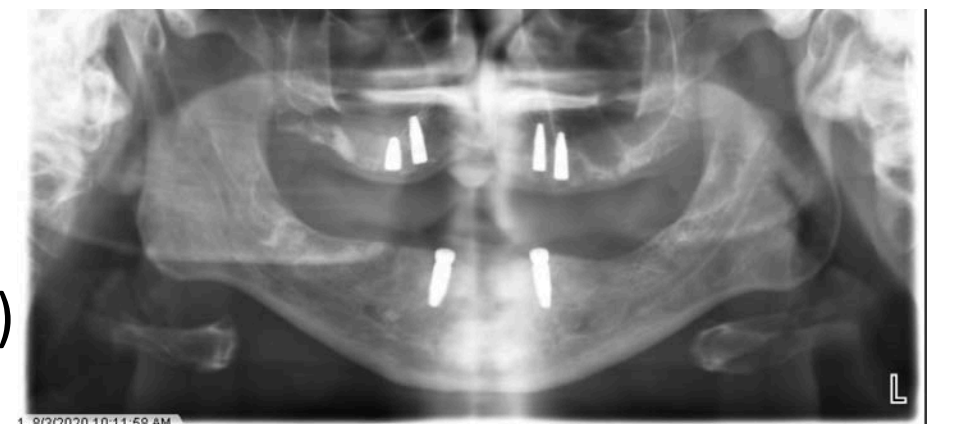


Siebert Class III Defect

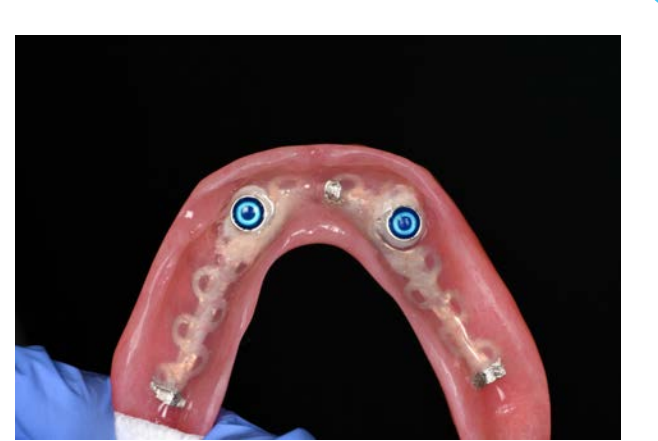
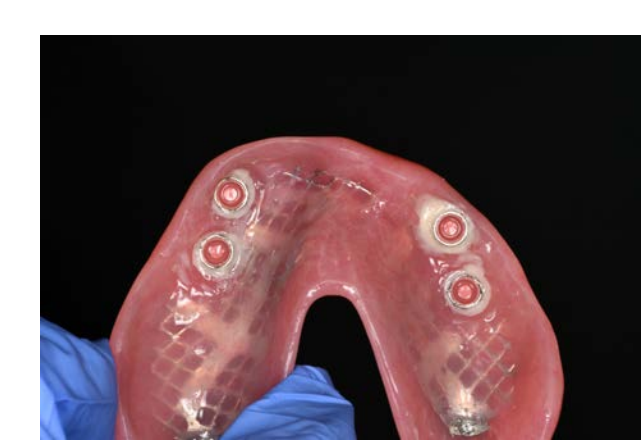
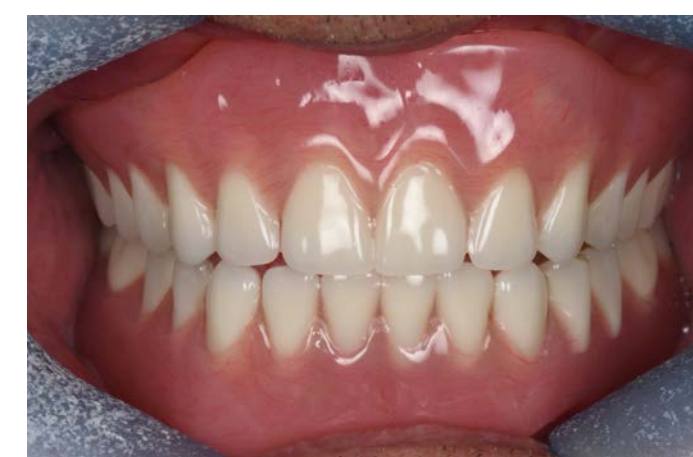Implant Placement

- Remaining mandibular dentition extracted with bone grafting
- Straumann Implant placement
- Mandibular implants torqued to 40 Ncm
 - Healing abutments placed
- Left maxillary sinus lift
- Maxillary implants torqued to 34 Ncm (insufficient)
 - Cover screw placed
 - Second stage successfully performed → healing abutments placed



Prosthesis and Locator Attachments



- Mandibular Prosthesis: Extra Light Retention (Blue)
- Maxillary Prosthesis: Light Retention (Pink)

- Maxillary and Mandibular prostheses fabricated with metal frame works
- Locators picked up chair side
- Patient returned for follow up to assess retention of prostheses
 - Mandibular adequate retention → blue
 - Maxillary slightly inadequate retention → pink

Chair-Side Pickup Technique

- Ream out acrylic on intaglio surface to allow for locator
 - Check with Color Transfer Applicators to confirm location and clearance
- Place plastic ring on implant abutment to prevent subgingival extrusion of acrylic
- Attach locator with pickup gasket to abutment
- Mix thin acrylic and fill reamed out area, seat denture
 - Simultaneously pick up a locator on each side to ensure proper seating
- Remove excess acrylic around locators

Conclusion

In the presence of a Siebert class III defect, maxillary and mandibular implant stabilized overdentures were successfully delivered to improve the smile and function of this patient. The esthetics of this case were improved both intra- and extra-orally. The patient displayed good occlusion and phonetics, and his vertical dimension was restored. Implant-stabilized prostheses are a great treatment options in cases where retention is not obtainable due to alveolar ridge defects.

